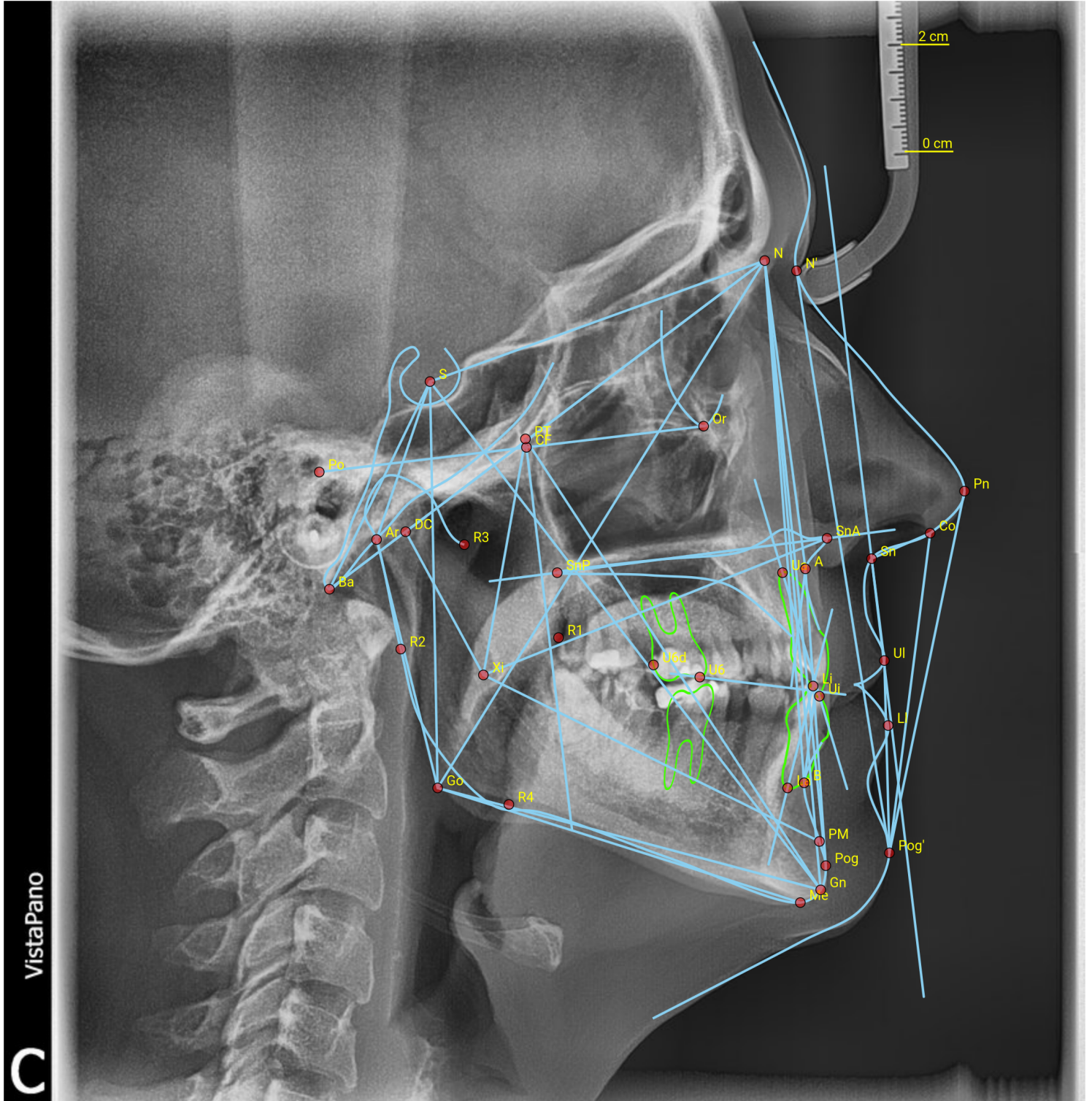




Patient ID: Sami Barketi (Male)
Date of birth: 1990-01-01 (35 years, 2 months)

Analysis type: Combined analyses
Stage: Before treatment



This report is indicative solely, any diagnoses should be made at the discretion and sole liability of the person utilizing this information.

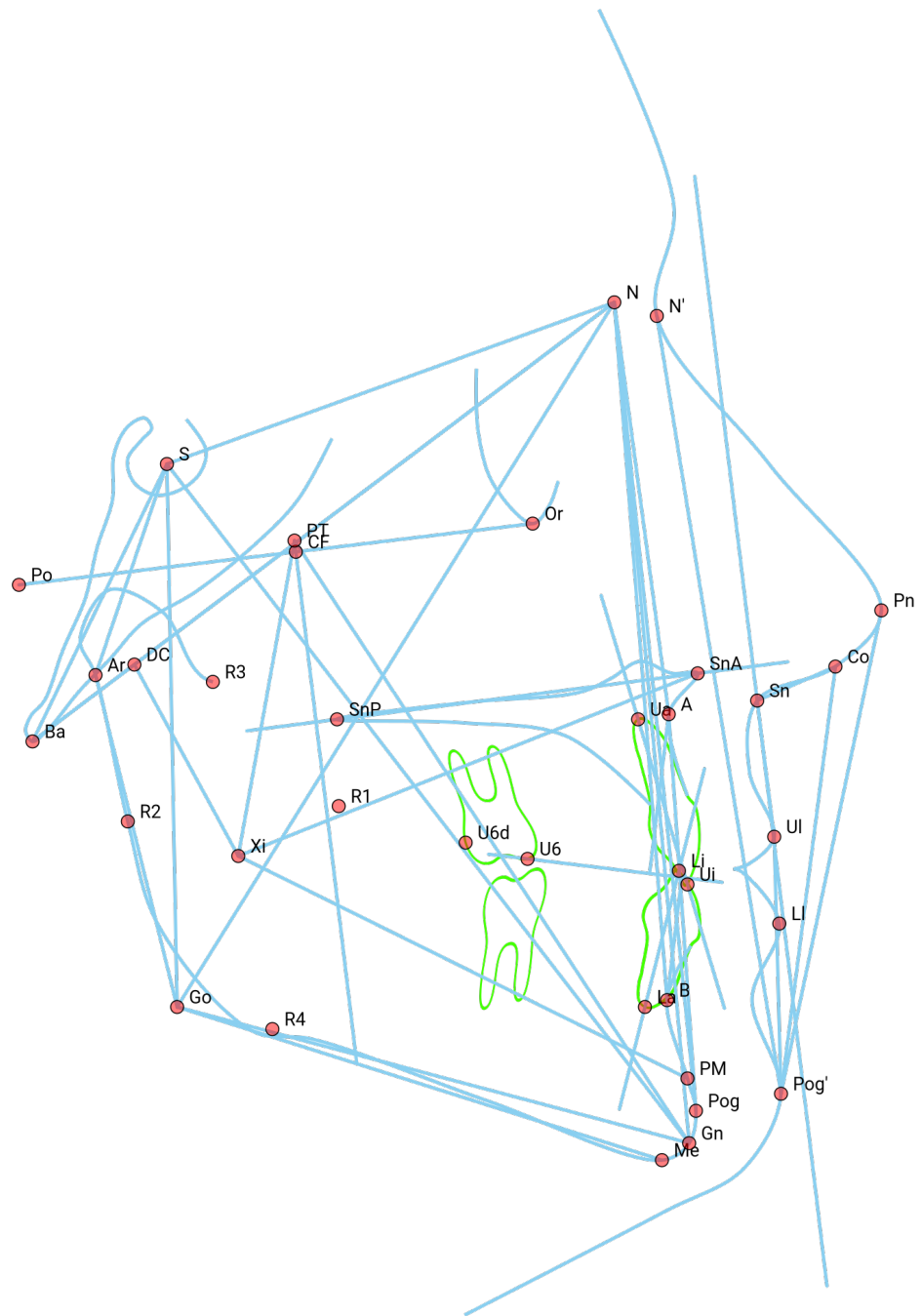


Patient ID: Sami Barketi (Male)

Analysis type: Combined analyses

Date of birth: 1990-01-01 (35 years, 2 months)

Stage: Before treatment



This report is indicative solely, any diagnoses should be made at the discretion and sole liability of the person utilizing this information.



Patient ID: Sami Barketi (Male)

Analysis type: Quick analysis

Date of birth: 1990-01-01 (35 years, 2 months)

Stage: Before treatment

| Nr | Parameter | Reference | Value | Diff. | Comment |
|--------------------------|--------------------------|-----------|--------|-------|--------------------|
| SKELETAL PATTERN: | | | | | |
| 1 | S-N-A Angle | 82 ± 2° | 77.7° | -4.3° | retrusive maxilla |
| 2 | S-N-B Angle | 80 ± 2° | 74.5° | -5.5° | retrusive mandible |
| 3 | A-N-B Angle | 2 ± 2° | 3.2° | +1.2° | |
| 4 | MP to S-N | 32 ± 4° | 37.4° | +5.4° | skeletal open bite |
| 5 | N-S-Ba | 130 ± 3° | 135.7° | +5.7° | skeletal Class II |
| 6 | PP to S-N | 8 ± 4° | 12.6° | +4.6° | skeletal deep bite |
| 7 | MP to PP | 24 ± 7° | 24.8° | +0.8° | |
| 8 | Index (N:ANS' / ANS':Me) | 80 ± 9% | 79.1% | -0.9% | |

This report is indicative solely, any diagnoses should be made at the discretion and sole liability of the person utilizing this information.



Patient ID: Sami Barketi (Male)

Analysis type: Bjork-Jarabak

Date of birth: 1990-01-01 (35 years, 2 months)

Stage: Before treatment

| Nr | Parameter | Reference | Value | Diff. | Comment |
|--------------------------|-------------------------------------|-------------|---------|---------|--|
| SKELETAL PATTERN: | | | | | |
| 1 | Saddle Angle (N-S-Ar) | 123 ± 5° | 128.6° | +5.6° | distal implantation of mandible, dolichocephal |
| 2 | Articulare Angle (S-Ar-Go) | 143 ± 6° | 147.5° | +4.5° | |
| 3 | Gonial Angle (Ar-Go-Me) | 130 ± 7° | 121.4° | -8.6° | skeletal deep bite |
| 4 | Sum of Posterior Angles | 396 ± 5° | 397.4° | +1.4° | |
| 5 | Upper Gonial Angle (N-Go-Ar) | 53.5 ± 1.5° | 45.7° | -7.8° | limited advancement of the chin |
| 6 | Lower Gonial Angle (N-Go-Me) | 72.5 ± 5.5° | 75.7° | +3.2° | |
| 7 | Anterior Cranial Base (N-S) | 71 ± 10 mm | 66.5 mm | -4.5 mm | |
| 8 | Posterior Cranial Base (S-Ar) | 32 ± 5 mm | 31.1 mm | -0.9 mm | |
| 9 | Ramus Height (Ar-Go) | 44 ± 5 mm | 47.8 mm | +3.8 mm | |
| 10 | Mandibular Body (Go-Gn) | 71 ± 8 mm | 74.1 mm | +3.1 mm | |
| 11 | Posterior Face Height (S-Go) | 82 ± 8 mm | 75.9 mm | -6.1 mm | |
| 12 | Anterior Face Height (N-Gn) | 102 ± 8 mm | 118 mm | +16 mm | |
| 13 | AFH/(AFH+PFH) | 61 ± 2% | 60.9% | -0.1% | |
| 14 | ACB - Mandibular Body (ACB : Go-Gn) | 100 ± 10% | 89.8% | -10.2% | |
| DENTAL PATTERN: | | | | | |
| 15 | Upper Incisor to S-N (Ui-Ua : S-N) | 102 ± 2° | 86.8° | -15.2° | retroclined upper incisors |



Patient ID: Sami Barketi (Male)

Analysis type: Downs

Date of birth: 1990-01-01 (35 years, 2 months)

Stage: Before treatment

| Nr | Parameter | Reference | Value | Diff. | Comment |
|--------------------------|--|--------------|--------|---------|---|
| SKELETAL PATTERN: | | | | | |
| 1 | Facial (Depth) Angle (FH: N-Pog) | 94 ± 3° | 89° | -5° | retruded chin, dolichofacial pattern, Class II tendency |
| 2 | Angle of Convexity (N-A : A-Pog) | 0 ± 5° | 3.6° | +3.6° | |
| 3 | A-B Plane (A-B : N-Pog) | -4.6 ± 4.6° | -6.1° | -1.5° | |
| 4 | Mandibular Plane Angle (MP : FH) | 22 ± 3° | 21.7° | -0.3° | |
| 5 | Y-Axis (S-Gn : FH) | 59.4 ± 3.8° | 59.2° | -0.2° | |
| DENTAL PATTERN: | | | | | |
| 6 | Occlusal Plane (Occ : FH) | 9.3 ± 3.8° | 13.7° | +4.4° | indicates Class II, open bite tendency, short ramus |
| 7 | Interincisal Angle (Ui-Ua : Li-La) | 135 ± 8° | 149.3° | +14.3° | retroclined incisors |
| 8 | Incisor to Occlusal Plane Angle (Li-La : Occ) | 14.5 ± 3.5° | 7.2° | -7.3° | retroclined lower incisors |
| 9 | Incisor to Mandibular Plane Angle (Li-La : MP) | 90 ± 5° | 86.5° | -3.5° | |
| 10 | Protrusion of Maxillary Incisors (Ui : A-Pog) | 2.7 ± 3.1 mm | 1 mm | -1.7 mm | |

This report is indicative solely, any diagnoses should be made at the discretion and sole liability of the person utilizing this information.



Patient ID: Sami Barketi (Male)

Analysis type: Rakosi

Date of birth: 1990-01-01 (35 years, 2 months)

Stage: Before treatment

| Nr | Parameter | Reference | Value | Diff. | Comment |
|--------------------------|---------------------------------------|-------------|--------|--------|--|
| SKELETAL PATTERN: | | | | | |
| 1 | Saddle Angle (N-S-Ar) | 123 ± 5° | 128.6° | +5.6° | distal implantation of mandible, dolichocephal |
| 2 | Articulare Angle (S-Ar-Go) | 143 ± 6° | 147.5° | +4.5° | |
| 3 | Gonial Angle (Ar-Go-Me) | 130 ± 7° | 121.4° | -8.6° | skeletal deep bite |
| 4 | Sum of Posterior Angles | 396 ± 5° | 397.4° | +1.4° | |
| 5 | Upper Gonial Angle (N-Go-Ar) | 53.5 ± 1.5° | 45.7° | -7.8° | limited advancement of the chin |
| 6 | Lower Gonial Angle (N-Go-Me) | 72.5 ± 5.5° | 75.7° | +3.2° | |
| 7 | S-N-A Angle | 82 ± 2° | 77.7° | -4.3° | retrusive maxilla |
| 8 | S-N-B Angle | 80 ± 2° | 74.5° | -5.5° | retrusive mandible |
| 9 | A-N-B Angle | 2 ± 2° | 3.2° | +1.2° | |
| 10 | S-N-Pog | 80 ± 1° | 75.9° | -4.1° | Class II malocclusion |
| 11 | S-N:Go-Me | 32 ± 5° | 37.4° | +5.4° | skeletal open bite |
| 12 | Base Plane Angle (SnA-SnP : Go-Me) | 25 ± 1° | 24.8° | -0.2° | |
| 13 | N-S-Gn | 66 ± 1° | 72.3° | +6.3° | |
| DENTAL PATTERN: | | | | | |
| 14 | Upper Incisor to S-N (Ui-Ua : S-N) | 102 ± 2° | 86.8° | -15.2° | retroclined upper incisors |
| 15 | Upper Incisor to PP (Ui-Ua : SnA-SnP) | 70 ± 5° | 80.6° | +10.6° | retroclined upper incisors |
| 16 | Upper Incisor to N-A (Ui-Ua : N-A) | 22 ± 4° | 9.1° | -12.9° | retroclined upper incisors |
| 17 | Lower Incisor to MP (Li-La : Go-Me) | 90 ± 5° | 86.5° | -3.5° | |
| 18 | Lower Incisor to N-B (Li-La : N-B) | 25 ± 4° | 18.4° | -6.6° | retroclined lower incisors |
| 19 | Interincisal Angle (Ui-Ua : Li-La) | 135 ± 8° | 149.3° | +14.3° | retroclined incisors |



Patient ID: Sami Barketi (Male)

Analysis type: Ricketts

Date of birth: 1990-01-01 (35 years, 2 months)

Stage: Before treatment

| Nr | Parameter | Reference | Value | Diff. | Comment |
|---|---|--------------|---------|---------|---|
| SKELETAL PATTERN: | | | | | |
| 1 | Cranial Deflection (Ba-N : FH) | 27 ± 3° | 30.2° | +3.2° | |
| 2 | Facial Axis (Ba-N : PT-Gn) | 90 ± 3.5° | 86.2° | -3.8° | facial growth in the vertical direction and/or Class II pattern |
| 3 | Facial (Depth) Angle (FH: N-Pog) | 94 ± 3° | 89° | -5° | retruded chin, dolichofacial pattern, Class II tendency |
| 4 | Facial Taper (Go-Gn: N-Pog) | 68 ± 4° | 69.3° | +1.3° | |
| MANDIBULAR POSITION: | | | | | |
| 5 | Mandibular Plane (Go-Gn : FH) | 19 ± 4.5° | 21.7° | +2.7° | |
| 6 | CORPUS LENGTH (Xi-PM) | 70 ± 5 mm | 70.1 mm | +0.1 mm | |
| 7 | Mandibular Arc (DC - Xi - PM) | 26 ± 3° | 35.2° | +9.2° | strong and square mandible |
| 8 | Ramus Xi Position (PT-Xi: FH) | 76 ± 4° | 73.1° | -2.9° | |
| 9 | Gonial Angle (Ar-Go-Gn) | 126 ± 7° | 118.7° | -7.3° | skeletal deep bite, tendency of horizontal growth |
| MAXILLARY POSITION: | | | | | |
| 10 | Maxillary Depth (FH : N-A) | 90 ± 5° | 90.7° | +0.7° | |
| 11 | Maxillary Height (N-CF-A) | 54 ± 5° | 61.6° | +7.6° | large maxillary height |
| 12 | Maxilla Inclination (PP: N-Pog) | 85 ± 3° | 88.5° | +3.5° | protruded chin or posterior maxillary rotation |
| 13 | FH to Palatal Plane (FH : PP) | 0 ± 5° | 0.5° | +0.5° | |
| MAXILLA TO MANDIBULA RELATIONSHIP: | | | | | |
| 14 | Convexity of Point A (A : N-Pog) | 2 ± 2 mm | 1.8 mm | -0.2 mm | |
| 15 | Lower Face Height (SnA-Xi-PM) | 47 ± 5° | 48° | +1° | |
| 16 | Face Height (Xi-Pog : N-Ba) | 66 ± 3° | 66.1° | +0.1° | |
| DENTAL PATTERN: | | | | | |
| 17 | Lower Incisor to A-Pog (Li : A-Pog) | 1 ± 2 mm | -0.1 mm | -1.1 mm | |
| 18 | Upper Molar to PtV (U6d : PTV) | 24 ± 3 mm | 19.3 mm | -4.7 mm | insufficient maxilla size for 2nd and 3rd molar eruption |
| 19 | Lower Incisor to A-Pog (Li-La : A-Pog) | 22 ± 4° | 18° | -4° | |
| 20 | Interincisal Angle (Ui-Ua : Li-La) | 135 ± 8° | 149.3° | +14.3° | retroclined incisors |
| 21 | Protrusion of Maxillary Incisors (Ui : A-Pog) | 2.7 ± 3.1 mm | 1 mm | -1.7 mm | |
| 22 | Hinge Axis Angle (DC - Go - Li) | 90 ± 3° | 81.9° | -8.1° | deep bite tendency |
| 23 | Overjet (Ui : Li) | 2.5 ± 2 mm | 1.4 mm | -1.1 mm | |
| 24 | Overbite (Ui : Occ) | 2.5 ± 2 mm | 1.7 mm | -0.8 mm | |

SOFT-TISSUE PATTERN:

This report is indicative solely, any diagnoses should be made at the discretion and sole liability of the person utilizing this information.



Patient ID: Sami Barketi (Male)

Analysis type: Ricketts

Date of birth: 1990-01-01 (35 years, 2 months)

Stage: Before treatment

| | | | | | |
|----|-----------------------------------|-----------|---------|---------|---------------------|
| 25 | Upper lip to E-Line (Ul : E-Line) | -4 ± 2 mm | -8.2 mm | -4.2 mm | recessive upper lip |
| 26 | Lower lip to E-Line (Ll : E-Line) | -2 ± 2 mm | -5.1 mm | -3.1 mm | recessive lower lip |

This report is indicative solely, any diagnoses should be made at the discretion and sole liability of the person utilizing this information.



Patient ID: Sami Barketi (Male)

Analysis type: Segner-Hasund

Date of birth: 1990-01-01 (35 years, 2 months)

Stage: Before treatment

| Nr | Parameter | Reference | Value | Diff. | Comment |
|-----------------------------|------------------------------------|-----------|---------|---------|---|
| SKELETAL PATTERN: | | | | | |
| 1 | S-N-A Angle | 82 ± 2° | 77.7° | -4.3° | retrusive maxilla |
| 2 | S-N-B Angle | 80 ± 2° | 74.5° | -5.5° | retrusive mandible |
| 3 | A-N-B Angle | 2 ± 2° | 3.2° | +1.2° | |
| 4 | MP to S-N | 32 ± 4° | 37.4° | +5.4° | skeletal open bite |
| 5 | S-N-Pog | 80 ± 1° | 75.9° | -4.1° | Class II malocclusion |
| 6 | N-S-Ba | 130 ± 3° | 135.7° | +5.7° | skeletal Class II |
| 7 | Gonial Angle (Ar-Go-Gn) | 126 ± 7° | 118.7° | -7.3° | skeletal deep bite, tendency of horizontal growth |
| 8 | Norderval Angle (B-Pog : Go-Me) | 58 ± 5° | 57.8° | -0.2° | |
| 9 | PP to S-N | 8 ± 4° | 12.6° | +4.6° | skeletal deep bite |
| 10 | MP to PP | 24 ± 7° | 24.8° | +0.8° | |
| 11 | H angle (hard tissue) | 8 ± 4° | 2.8° | -5.2° | recessed upper lip or prognathic soft tissue chin |
| 12 | H angle (soft tissue) | 11 ± 4° | 7.6° | -3.4° | |
| 13 | Wits (AO : BO) | 0 ± 2 mm | -4.5 mm | -4.5 mm | skeletal Class III tendency |
| 14 | Index (N:ANS' / ANS':Me) | 80 ± 9% | 79.1% | -0.9% | |
| 15 | Pog to N-B | 2 ± 2 mm | 2.9 mm | +0.9 mm | |
| DENTAL PATTERN: | | | | | |
| 16 | Interincisal Angle (Ui-Ua : Li-La) | 135 ± 8° | 149.3° | +14.3° | retroclined incisors |
| 17 | Upper Incisor to N-A (Ui-Ua : N-A) | 22 ± 4° | 9.1° | -12.9° | retroclined upper incisors |
| 18 | Lower Incisor to N-B (Li-La : N-B) | 25 ± 4° | 18.4° | -6.6° | retroclined lower incisors |
| 19 | Upper Incisor to N-A (Ui : N-A) | 4 ± 2 mm | -0.5 mm | -4.5 mm | retrusive upper incisors |
| 20 | Lower Incisor to N-B (Li : N-B) | 4 ± 2 mm | 3 mm | -1 mm | |
| SOFT-TISSUE PATTERN: | | | | | |
| 21 | Nasolabial Angle (Ul-Sn-Co) | 109 ± 8° | 106.4° | -2.6° | |



Patient ID: Sami Barketi (Male)

Analysis type: Full analysis

Date of birth: 1990-01-01 (35 years, 2 months)

Stage: Before treatment

| Nr | Parameter | Reference | Value | Diff. | Comment |
|-----------------------------|--|-------------|---------|---------|--|
| OTHOPEDECS: | | | | | |
| 1 | AFH/(AFH+PFH) | 61 ± 2% | 60.9% | -0.1% | |
| 2 | Facial (Depth) Angle (FH: N-Pog) | 94 ± 3° | 89° | -5° | retruded chin, dolichofacial pattern, Class II tendency |
| 3 | Y-Axis (S-Gn : FH) | 59.4 ± 3.8° | 59.2° | -0.2° | |
| 4 | Lower Face Height (SnA-Xi-PM) | 47 ± 5° | 48° | +1° | |
| 5 | MP to PP | 24 ± 7° | 24.8° | +0.8° | |
| 6 | Wits (AO : BO) | 0 ± 2 mm | -4.5 mm | -4.5 mm | skeletal Class III tendency |
| MAXILLA: | | | | | |
| 7 | Maxillary Depth (FH : N-A) | 90 ± 5° | 90.7° | +0.7° | |
| 8 | S-N-A Angle | 82 ± 2° | 77.7° | -4.3° | retrusive maxilla |
| 9 | PP to S-N | 8 ± 4° | 12.6° | +4.6° | skeletal deep bite |
| MANDIBLE: | | | | | |
| 10 | Ramus Xi Position (PT-Xi: FH) | 76 ± 4° | 73.1° | -2.9° | |
| 11 | S-N-B Angle | 80 ± 2° | 74.5° | -5.5° | retrusive mandible |
| 12 | MP to S-N | 32 ± 4° | 37.4° | +5.4° | skeletal open bite |
| 13 | SN / GoMe | 100 ± 5% | 93.6% | -6.4% | |
| 14 | Gonial Angle (Ar-Go-Me) | 130 ± 7° | 121.4° | -8.6° | skeletal deep bite |
| ORTHODONTICS: | | | | | |
| 15 | Interincisal Angle (Ui-Ua : Li-La) | 135 ± 8° | 149.3° | +14.3° | retroclined incisors |
| 16 | Lower Incisor to A-Pog (Li : A-Pog) | 1 ± 2 mm | -0.1 mm | -1.1 mm | |
| 17 | Incisor to Mandibular Plane Angle (Li-La : MP) | 90 ± 5° | 86.5° | -3.5° | |
| 18 | Upper Incisor to N-A (Ui-Ua : N-A) | 22 ± 4° | 9.1° | -12.9° | retroclined upper incisors |
| 19 | Lower Incisor to N-B (Li-La : N-B) | 25 ± 4° | 18.4° | -6.6° | retroclined lower incisors |
| 20 | Upper Incisor to N-A (Ui : N-A) | 4 ± 2 mm | -0.5 mm | -4.5 mm | retrusive upper incisors |
| 21 | Lower Incisor to N-B (Li : N-B) | 4 ± 2 mm | 3 mm | -1 mm | |
| 22 | Upper Molar to PtV (U6d : PTV) | 24 ± 3 mm | 19.3 mm | -4.7 mm | insufficient maxilla size for 2nd and 3rd molar eruption |
| 23 | N-S-Ba | 130 ± 3° | 135.7° | +5.7° | skeletal Class II |
| 24 | A-N-B Angle | 2 ± 2° | 3.2° | +1.2° | |
| 25 | Index (N:ANS' / ANS':Me) | 80 ± 9% | 79.1% | -0.9% | |
| SOFT-TISSUE PATTERN: | | | | | |
| 26 | Upper lip to E-Line (Ul : E-Line) | -4 ± 2 mm | -8.2 mm | -4.2 mm | recessive upper lip |
| 27 | Lower lip to E-Line (Ll : E-Line) | -2 ± 2 mm | -5.1 mm | -3.1 mm | recessive lower lip |

This report is indicative solely, any diagnoses should be made at the discretion and sole liability of the person utilizing this information.



Patient ID: Sami Barketi (Male)

Analysis type: Full analysis

Date of birth: 1990-01-01 (35 years, 2 months)

Stage: Before treatment

| | | | | | |
|----|--|-----------|---------|---------|---------------------|
| 28 | Upper lip to Steiner's S-line (UI : Co-Pog') | 0 ± 0 mm | -5.5 mm | -5.5 mm | recessive upper lip |
| 29 | Lower lip to Steiner's S-line (LI : Co-Pog') | 0 ± 0 mm | -3.2 mm | -3.2 mm | recessive lower lip |
| 30 | Nasolabial Angle (UI-Sn-Co) | 109 ± 8° | 106.4° | -2.6° | |
| 31 | TVL to Upper lip | 3 ± 1 mm | 0.1 mm | -2.9 mm | |
| 32 | TVL to Lower lip | 1 ± 1 mm | -0.6 mm | -1.6 mm | |
| 33 | TVL to Pog' | -3 ± 1 mm | -3.2 mm | -0.2 mm | |

This report is indicative solely, any diagnoses should be made at the discretion and sole liability of the person utilizing this information.



Patient ID: Sami Barketi (Male)

Analysis type: Wits

Date of birth: 1990-01-01 (35 years, 2 months)

Stage: Before treatment

| Nr | Parameter | Reference | Value | Diff. | Comment |
|--------------|----------------|-----------|---------|---------|-----------------------------|
| WITS: | | | | | |
| 1 | Wits (AO : BO) | 0 ± 2 mm | -4.5 mm | -4.5 mm | skeletal Class III tendency |



Patient ID: Sami Barketi (Male)

Analysis type: Tweed

Date of birth: 1990-01-01 (35 years, 2 months)

Stage: Before treatment

| Nr | Parameter | Reference | Value | Diff. | Comment |
|---------------|--|-----------|-------|-------|---------|
| TWEED: | | | | | |
| 1 | Incisor to Mandibular Plane Angle (Li-La : MP) | 90 ± 5° | 86.5° | -3.5° | |
| 2 | Frankfurt to Mandibular Incisor Angle | 68 ± 7° | 69.2° | +1.2° | |
| 3 | Frankfurt to Mandibular Plane Angle (Po-Or : MP) | 22 ± 5° | 24.3° | +2.3° | |

This report is indicative solely, any diagnoses should be made at the discretion and sole liability of the person utilizing this information.



Patient ID: Sami Barketi (Male)

Analysis type: Steiner

Date of birth: 1990-01-01 (35 years, 2 months)

Stage: Before treatment

| Nr | Parameter | Reference | Value | Diff. | Comment |
|-----------------------------|--|-----------|---------|---------|---|
| SKELETAL PATTERN: | | | | | |
| 1 | S-N-A Angle | 82 ± 2° | 77.7° | -4.3° | retrusive maxilla |
| 2 | S-N-B Angle | 80 ± 2° | 74.5° | -5.5° | retrusive mandible |
| 3 | A-N-B Angle | 2 ± 2° | 3.2° | +1.2° | |
| 4 | Occlusal Plane to S-N | 14 ± 3° | 26.7° | +12.7° | long face or vertically growing individuals, skeletal open bite |
| 5 | MP to S-N | 32 ± 4° | 37.4° | +5.4° | skeletal open bite |
| DENTAL PATTERN: | | | | | |
| 6 | Upper Incisor to N-A (Ui-Ua : N-A) | 22 ± 4° | 9.1° | -12.9° | retroclined upper incisors |
| 7 | Upper Incisor to N-A (Ui : N-A) | 4 ± 2 mm | -0.5 mm | -4.5 mm | retrusive upper incisors |
| 8 | Lower Incisor to N-B (Li : N-B) | 4 ± 2 mm | 3 mm | -1 mm | |
| 9 | Lower Incisor to N-B (Li-La : N-B) | 25 ± 4° | 18.4° | -6.6° | retroclined lower incisors |
| 10 | Interincisal Angle (Ui-Ua : Li-La) | 135 ± 8° | 149.3° | +14.3° | retroclined incisors |
| 11 | Pog to N-B | 2 ± 2 mm | 2.9 mm | +0.9 mm | |
| 12 | Holdaway ratio (Li:N-B : Pog:N-B) | 0 ± 2 mm | 0.2 mm | +0.2 mm | |
| SOFT-TISSUE PATTERN: | | | | | |
| 13 | Upper lip to Steiner's S-line (Ul : Co-Pog') | 0 ± 0 mm | -5.5 mm | -5.5 mm | recessive upper lip |
| 14 | Lower lip to Steiner's S-line (Ll : Co-Pog') | 0 ± 0 mm | -3.2 mm | -3.2 mm | recessive lower lip |



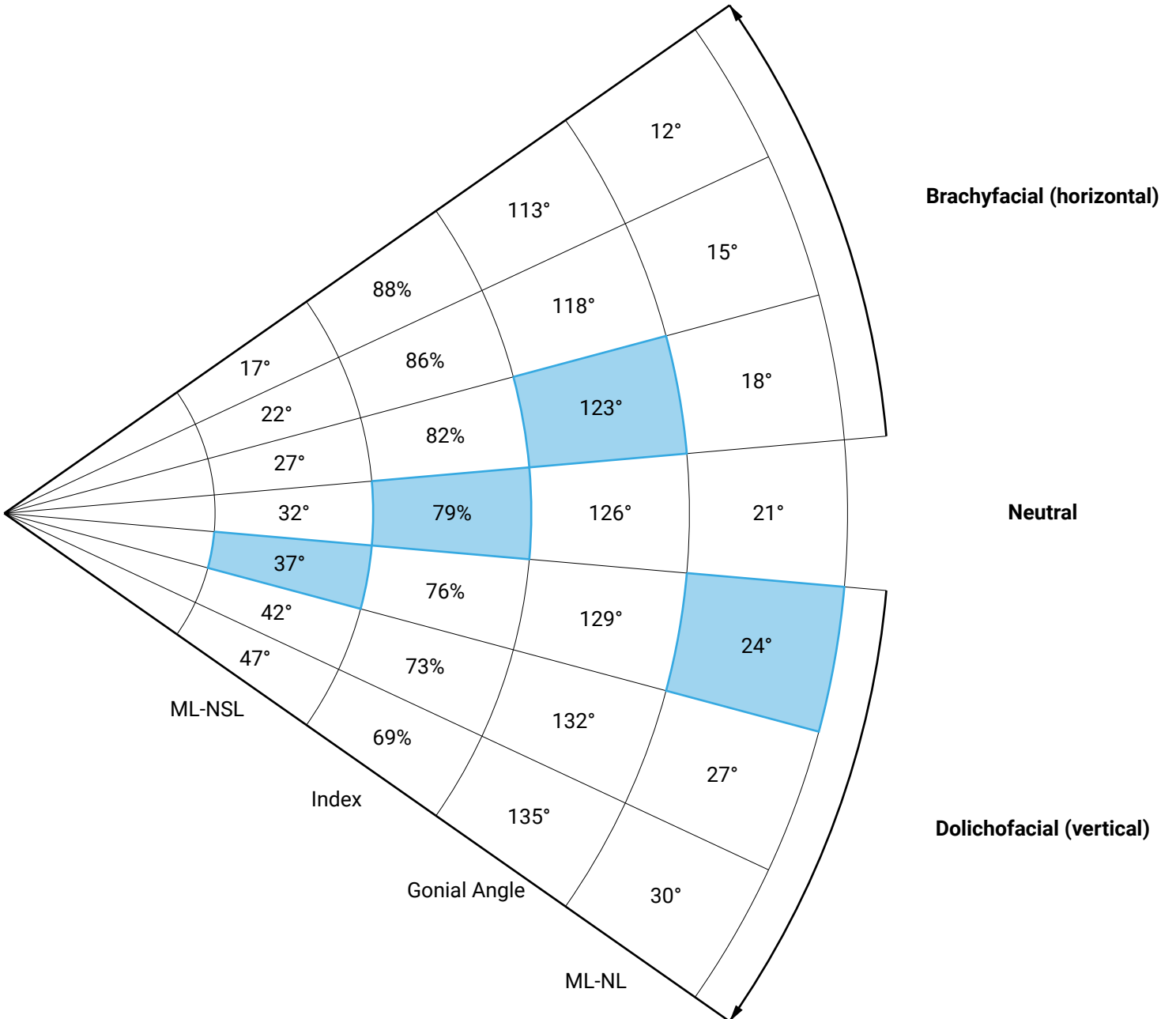
Patient ID: Sami Barketi (Male)

Analysis type: Combined analyses

Date of birth: 1990-01-01 (35 years, 2 months)

Stage: Before treatment

FACIAL GROWTH PATTERN



This report is indicative solely, any diagnoses should be made at the discretion and sole liability of the person utilizing this information.



Patient ID: Sami Barketi (Male)
Date of birth: 1990-01-01 (35 years, 2 months)

Analysis type: Combined analyses
Stage: Before treatment

HARMONY BOX

Table with 7 columns: SNA, NL-NSL, NSBa, ML-NSL, SNB, ML-NL. Rows are categorized into Retrognath, Orthognath, and Prognath. A red line graph is overlaid on the NL-NSL and ML-NSL columns.

Tendency:

Retrognath face type. Harmonic face, all values lie inside the box.

Sagittal basal relation: distal (ANB = 3.2°)
Vertical basal relation: normal (Face index = 79.1%)
RIB value: normal (RIB = 2.3°)

This report is indicative solely, any diagnoses should be made at the discretion and sole liability of the person utilizing this information.